

## Case Report

# Role of EUS-FNA in Recurrent Lung Cancer: Maximum Results with Minimum (minimally invasive) Effort

Ana M. Ioncica<sup>1</sup>, Mehmet Bektas<sup>2</sup>, Rei Suzuki<sup>3</sup>, Adrian Saftoiu<sup>1</sup>, Everson L.A. Artifon<sup>4</sup>, Manoop S. Bhutani<sup>3\*</sup>

<sup>1</sup> Research Center of Gastroenterology and Hepatology, University of Medicine and Pharmacy of Craiova, Romania; <sup>2</sup> Department of Gastroenterology, Ankara University Faculty of Medicine, Ankara, Turkey; <sup>3</sup> Department of Gastroenterology, Hepatology and Nutrition, UT MD Anderson Cancer Center, Houston, Texas, USA; <sup>4</sup> Department of Gastroenterology, University of São Paulo (USP), São Paulo, Brazil

### ABSTRACT

Endoscopic ultrasound-guided fine needle aspiration (EUS-FNA) is an excellent method for primary lung cancer staging. We describe a 66-year-old male who underwent EUS-FNA for the diagnosis of recurrent lung cancer. Two years after initial radiation therapy followed by complete remission, routine follow-up imaging study revealed a mass in the right hilum. Trans-esophageal EUS revealed a 1.3-cm mass and the result of EUS-FNA was consistent with non-small lung cancer. EUS-FNA can play an important role in diagnosis of recurrent lung cancer as well as primary staging avoiding the more invasive diagnostic technique.

**Keywords:** lung cancer; endoscopic ultrasound, fine-needle aspiration, minimally invasive

Ioncica AM, Bektas M, Suzuki R, Saftoiu A, Artifon ELA, Bhutani MS. Role of EUS-FNA in Recurrent Lung Cancer: Maximum Results with Minimum (minimally invasive) Effort. *Endosc Ultrasound* 2013; 2(1): 102-104

### INTRODUCTION

Endoscopic ultrasound (EUS) and EUS-guided fine needle aspiration (EUS-FNA) can play an important role in staging of lung cancer as it is very useful for sampling mediastinal lymph nodes. We here present our experience with a patient suggesting an even greater role for EUS in lung cancer.<sup>1</sup>

### CASE REPORT

We present the case of a 66-year-old male with a history of squamous cell carcinoma in the right upper lobe in stage IA (T<sub>1a</sub>N<sub>0</sub>M<sub>0</sub>) enrolled in a stereotactic body radiation therapy protocol. He was in complete clinical and radiologic remission. Two years later a routine follow up combined positron emission tomography-computed tomography (PET-CT) scan revealed an enlarged fluorodeoxyglucose (FDG) - avid right lower lobe lesion measuring 1.3 cm × 1 cm in size (Fig. 1A, B). Due to the patient's significant co-morbidities (coronary artery disease, 5 coronary stents, bilateral carotid endarterectomy, renal artery stent placement, sleep apnea and chronic obstructive pulmonary disease)

and deep seated nature of the lesion, a CT-guided biopsy or a mediastinoscopy were considered to be too invasive and with increased risk. The oncologist referred the patient for EUS-FNA as the first minimally invasive procedure to possibly sample this lesion. EUS was performed with an Olympus linear echoendoscope after informed consent. A 1.3-cm hypoechoic lesion was identified in the hilum of the right lung very close to the esophageal wall correlating with the CT-PET findings (Fig. 2A). After identification of an avascular plane the lesion was sampled by trans-esophageal EUS-FNA with a 25-G needle (2 passes) and a 22-G needle (3 additional passes) and sent to cytopathology (Fig. 2B). There were no immediate or delayed post-procedure complications. The cytopathology diagnosis was consistent with non-small cell (squamous) lung carcinoma and the patient was referred to oncology for further therapy.

### DISCUSSION

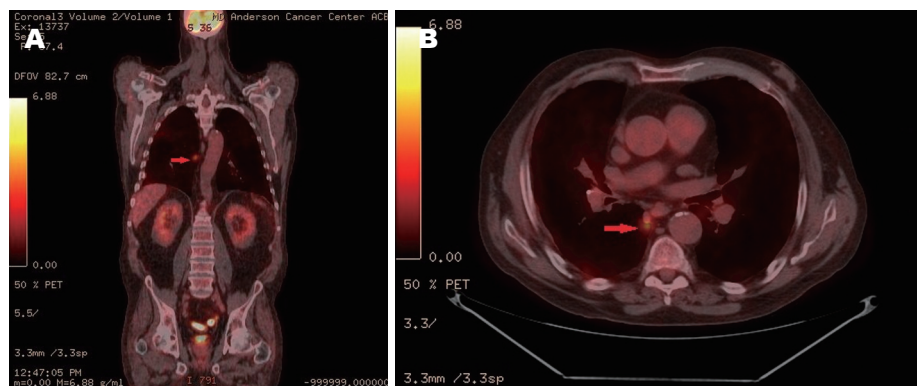
EUS-FNA has been proven to be an excellent method for the detection, characterization and staging of mediastinal masses.<sup>1</sup> The method has been predominantly used to diagnose mediastinal lymphadenopathy of unknown origin and to stage lung cancer in a minimally invasive fashion. Patients with malignancies at high risk for recurrence after primary treatment are routinely followed with periodic imaging studies such as CT and more recently PET-CT.<sup>2,3</sup>

\*To whom correspondence should be addressed.

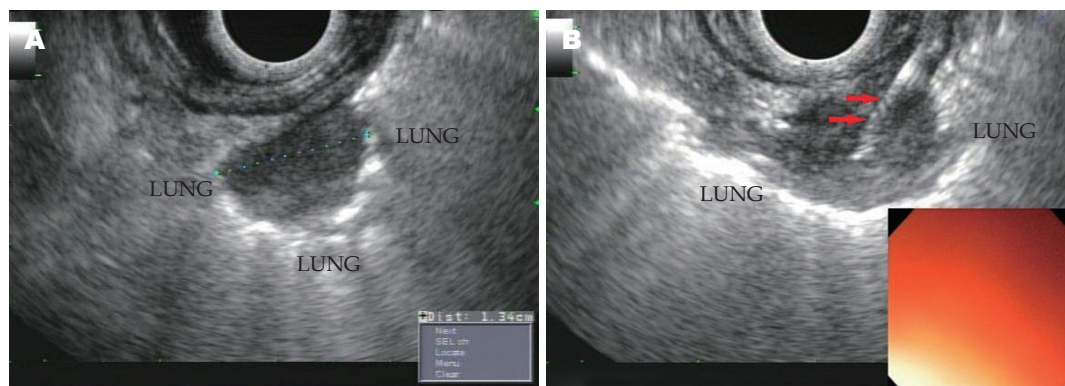
E-mail: [manoop.bhutani@mdanderson.org](mailto:manoop.bhutani@mdanderson.org)

Received: 2012-11-02; Accepted: 2012-12-28

doi: 10.7178/eus.05.008



**Figure 1.** FDG-PET/CT. A: Whole body coronal PET/CT image of a  $^{18}\text{F}$ -FDG uptake in the right lower lobe lesion (arrow); B: PET/CT image - transverse plane of  $^{18}\text{F}$ -FDG uptake in the right lower lobe lesion (arrow). FDG-PET/CT: fluorodeoxyglucose-positron emission tomography-computed tomography.



**Figure 2.** Images of hypoechoic, non-homogenous lung lesion of 1.3 cm × 1 cm surrounded by normal lung tissue, close to the esophageal wall. A: EUS; B: EUS-FNA. EUS-FNA: endoscopic ultrasound-guided fine needle aspiration.

However, a tissue confirmation of malignancy is usually needed after visualization of suspicious lesions during cross-sectional imaging.

Thoracoscopy, mediastinoscopy and CT-guided needle biopsy were previously considered the main techniques for the assessment of tissue diagnosis in lung cancer. All are invasive techniques associated with patient discomfort, high morbidity, as well as a rate of minor complication in the range of 2.5%-17% and major complications of 0.3%-1%.<sup>4,5</sup> This is why this patient was subjected to EUS-FNA as a minimally invasive alternative for the confirmation of tissue diagnosis. There are a number of papers that attest to the role of EUS-FNA in staging of lung cancer as well as in diagnosis of primary tumors.<sup>6-8</sup> But only a few have described the potential role of EUS-FNA in following patients with recurrent lung cancer after radiochemotherapy or curative treatment.<sup>9-11</sup>

Our case underlines the potential importance of EUS-FNA as a minimally invasive technique not only for staging but also for the diagnosis of recurrent lung cancer, thus preventing the need for more invasive techniques like thoracotomy, thoracoscopy and/or mediastinoscopy. EUS-FNA may be a part of post-treatment surveillance of patients with non-small cell lung cancer. However, further study is required to establish the role of EUS-FNA in comparison to other modalities used for the same purpose.

## REFERENCES

- Catalano MF, Rosenblatt ML, Chak A, et al. Endoscopic ultrasound-guided fine needle aspiration in the diagnosis of mediastinal masses of unknown origin. *Am J Gastroenterol* 2002; 97: 2559-65.
- Toba H, Kondo K, Otsuka H, et al. Diagnosis of the presence of lymph node metastasis and decision of operative indication using fluorodeoxyglucose-positron emission tomography and computed tomography in patients with primary lung cancer. *J Med Invest* 2010; 57: 305-13.
- Hellwig D, Groschel A, Graeter TP, et al. Diagnostic performance and prognostic impact of FDG-PET in suspected recurrence of surgically treated non-small cell lung cancer. *Eur J Nucl Med Mol Imaging* 2006; 33: 13-21.
- Priola AM, Priola SM, Cataldi A, et al. Diagnostic accuracy and complication rate of CT-guided fine needle aspiration biopsy of lung lesions: a study based on the experience of the cytopathologist. *Acta Radiol* 2010; 51: 527-33.
- Ernst A, Gangadharan SP. A good case for a declining role for mediastinoscopy just got better. *Am J Respir Crit Care Med* 2008; 177: 471-2.
- Silvestri GA, Hoffman BJ, Bhutani MS, et al. Endoscopic ultrasound with fine-needle aspiration in the diagnosis and staging of lung cancer. *Ann Thorac Surg* 1996;61:1441-5; discussion 1445-6.
- Fritscher-Ravens A. Endoscopic ultrasound evaluation in the diagnosis and staging of lung cancer. *Lung Cancer* 2003; 41: 259-67.

8. Hernandez A, Kahaleh M, Olazagasti J, et al. EUS-FNA as the initial diagnostic modality in centrally located primary lung cancers. *J Clin Gastroenterol* 2007; 41: 657-60.
9. Singh S, Thakur M. Diagnosis of recurrent lung cancer in the mediastinum using endosonographically guided fine-needle aspiration biopsy. *J Clin Ultrasound* 2009; 37: 230-2.
10. Lai R. Endoscopic ultrasound-guided fine needle aspiration for diagnosis of recurrent nonsmall cell lung cancer. *Ann Thorac Surg* 2005; 80: 2346-9.
11. Kim H, Chung SJ, Kim SG, et al. Endoscopic Ultrasonography-guided Fine Needle Aspiration for Computed Tomography-negative and Positron Emission Tomography-positive Mediastinal Lymph Node in a Patient with Recurrent Lung Cancer. *Gut Liver* 2007; 1: 90-2.

